

Abstract Type : Poster
Presentation No. : PDL 028

A Case Report of Liver Infarction after Tamoxifen Use in Encapsulated Peritoneal Fibrosis (EPS) in an Autosomal Dominant Polycystic Kidney Disease (ADPKD) patient

Won Keun Park¹, Hyunsuk Kim¹, Kwang Eon Shim¹, Jung hun Lee¹, Hae min Jeong¹, Kook hwan Oh², Jong-Woo Yoon¹

¹Department of Internal Medicine, Chuncheon Sacred Heart Hospital, Korea, Republic of

²Department of Internal Medicine, Seoul National University Hospital, Korea, Republic of

Case Study:

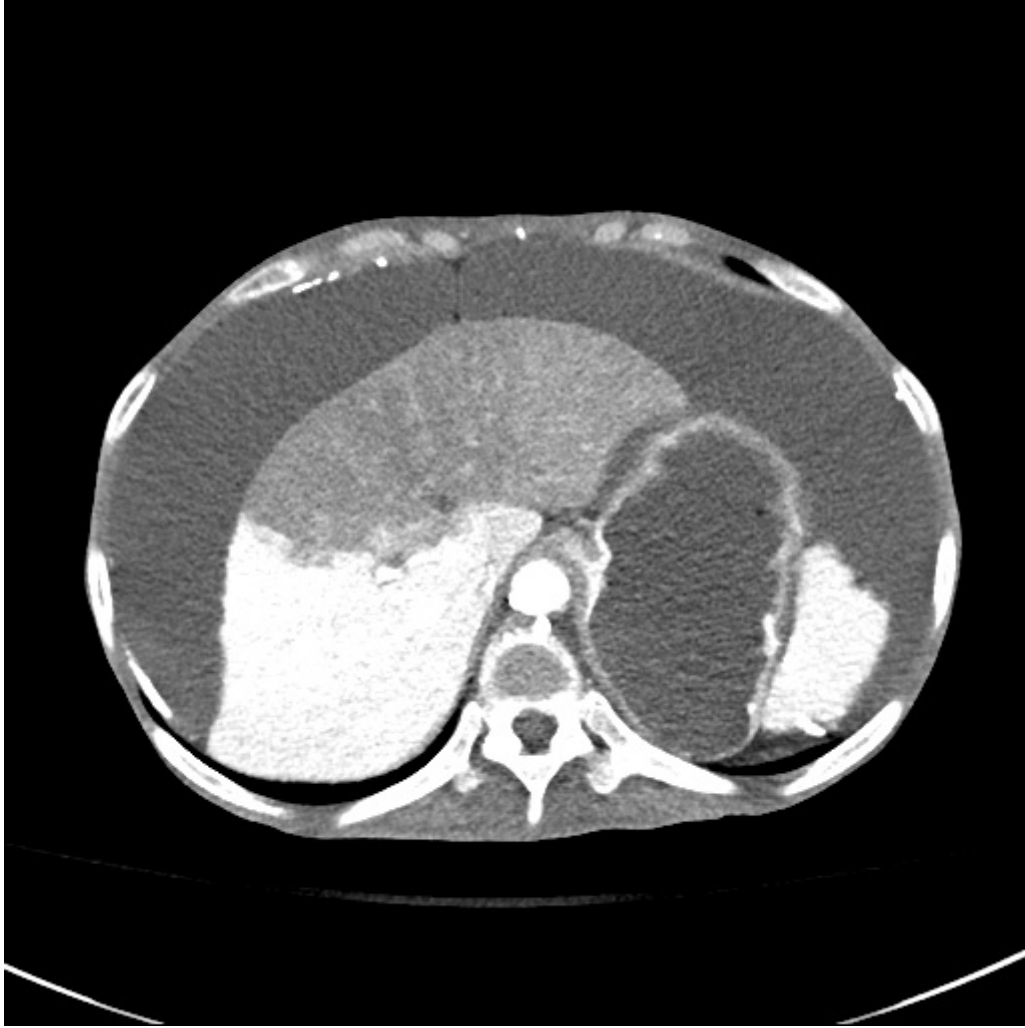
Encapsulated Peritoneal Fibrosis (EPS) is a fatal complication that can occur after long-term peritoneal dialysis, and tamoxifen can be used for its prevention and treatment. Tamoxifen is known to increase the risk of idiopathic venous thromboembolism. Reported herein is a case of liver infarction that occurred during the use of tamoxifen for the treatment of EPS.

A 49-year-old female patient was admitted with abdominal pain that suddenly occurred during hemodialysis. The patient was diagnosed end stage renal disease due to ADPKD and had been receiving peritoneal dialysis for 20-years and had been switched to hemodialysis as EPS had been developed. Tamoxifen 10mg and prednisolone 20mg were administered for 8 months for EPS.

The vital signs was stable, along with the WBC and CRP, which were 6,500 / μ L and 9.3 mg/dL, respectively. Infection was thus ruled out, and no other laboratory abnormalities were seen. In the contrast CT, the Lt. hepatic lobe was hardly illuminated, leading to a diagnosis of liver infarction. Liver enzyme and LDH was serially measured to monitor the hepatic ischemic change, and there were no abnormal findings for 2 days. No significant findings were obtained in the echocardiogram, and electrocardiogram showed normal sinus rhythm, which was performed for the of the possible embolic sources. The patient was later discharged as the pain was gradually alleviated.

The present patient is deemed to have presented liver infarction due to the tamoxifen side effect that was used for his EPS treatment, and an investigation of additional incidence and thorough monitoring for such complication are necessary in the treatment of similar cases.

Hepatic infarction



ADPKD

